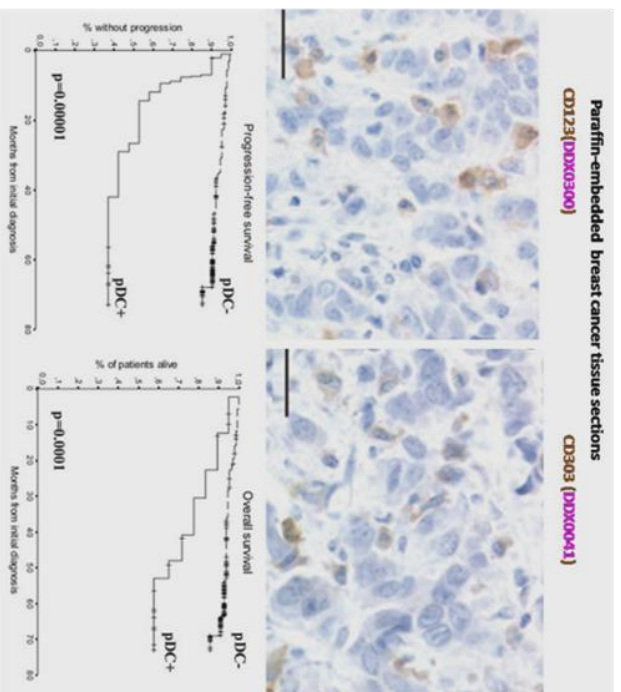
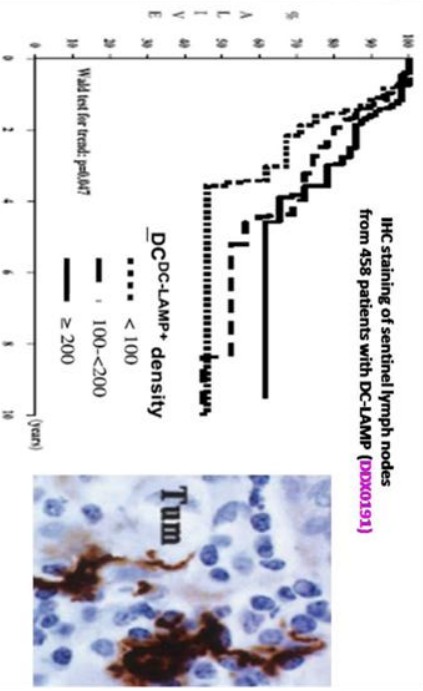


## Disease immunomonitoring

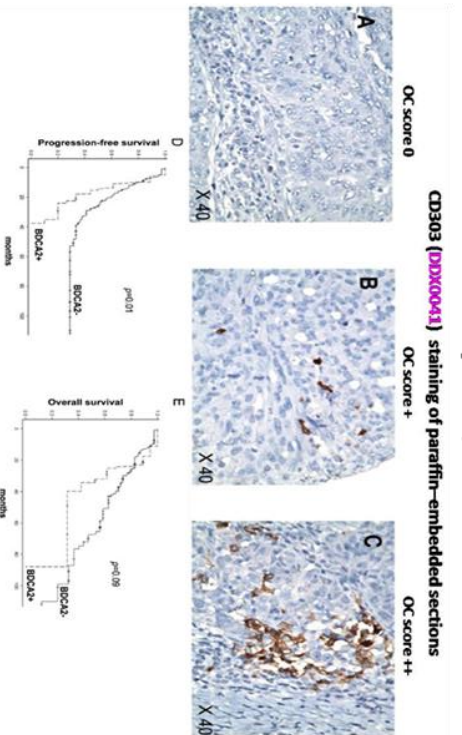
**Breast cancer**  
**Treilleux I et al, 2004**



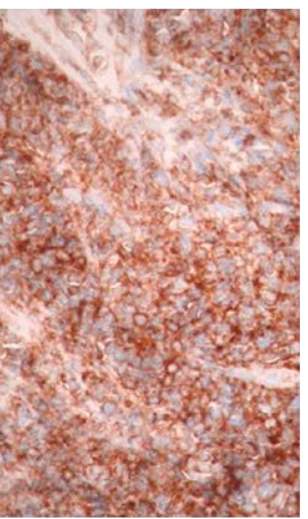
**Melanoma**  
**Movassagh M et al, 2004**  
**Elliott B et al, 2007**



**Ovarian cancer**  
**Labidi-Galy SI et al, 2012**



**Blastic Plasmacytoid Dendritic Cell Neoplasms (BPDCN)**  
**Julia F et al, 2014**



**CD303 (DDX0043) staining of skin biopsy**

60 Avenue Rockefeller-F-69008 Lyon Tel : +33 (0)472 717 403/Fax :+33(0) 478 001 436

[www.dendritics.net](http://www.dendritics.net)

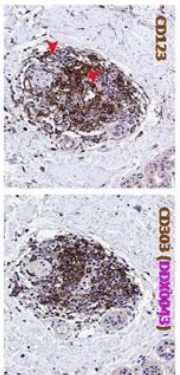
[contact@dendritics.net](mailto:contact@dendritics.net)

## Disease immunomonitoring

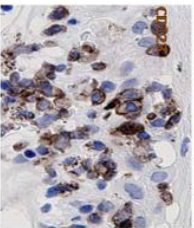
### Lupus

Verni W. et al, 2009

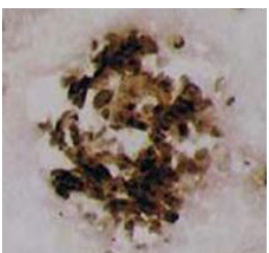
Dermal PDC nodules



Disease type (number of cases)	Frequency of PDC infiltration
SLE (18)	13 (72.2)
CLE (56)	54 (96.4)
Total (74)	67 (91.5)

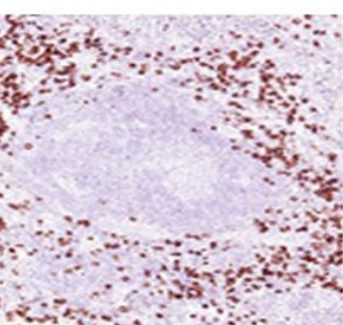



**Lung tumor**  
**Tumor**  
**Normal**



**MMP12 (DDX0280)**  
**Kikuchi**  
**Pr F Berger, Lyon Sud**

**CD303 staining (DDX0041)**  
**Normal tonsil**  
**Kikuchi's syndrome**



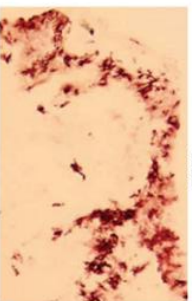
**Langerhans cell histiocytosis**

Gautier G et al, 2006

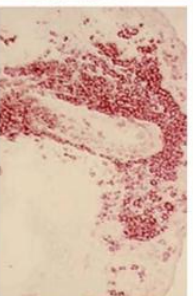
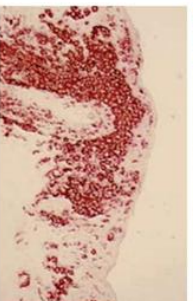
CD1a

SEMAG6A (DDX0462)

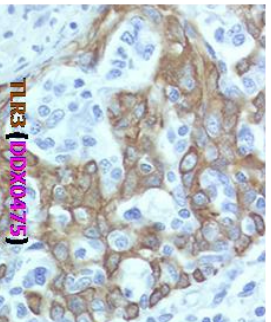
Normal skin



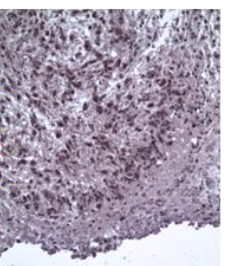
LC histiocytosis



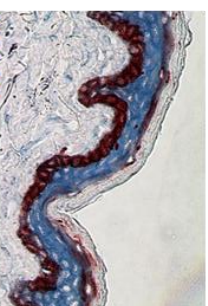
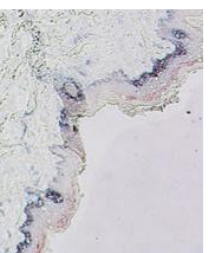
**Breast tumor**



**Glioblastoma**



**Psoriasis**  
**Normal skin**  
**Psoriasis skin**



**Eosophil (DDX0030)**